Content available at: https://sccti.in/archive

Stem Cells and Cellular Therapy International

Official Journal of Indian Stem Cell Study Group Association

Journal homepage: https://sccti.in/

Original Research Article

Stem cell therapy in pterygium, our experience

Gunasagar Das[1]*, Preetinanda Manaswini Dash[2]

[1]Dept. of Ophthalmology, Sambalpur, Odisha, India

[2]Multidisciplinary Research Unit (MRU), Bhima Bhoi Medical College & Hospital (BBMCH), Balangir, Odisha, India

Abstract

Purpose: Pterygium is a fibrovascular growth that invades the corneal surface within the interpalpebral fissure exposed to the atmosphere. Surgical excision is the mainstay of treatment; however recurrence remains a concern. This study describes the outcome observed after an innovative autologous conjunctival transplantation done by a single surgeon between the year 2006 and 2023.

Materials and Methods: Thirty patients with primary pterygium have been included in this study. Bare sclera excision with autolologous conjunctival transplantation was done in all the cases. In 2 cases, conjunctiva was retrieved from the upper bulbar area of the globe and transplanted as such on excised part. In the rest 28 cases, the tissue was retrieved from the upper limbal area extending two clock hours in length and three mm. wide (2 mm posterior and 1 mm anterior to the limbal line) and transplanted circumferentially in barrage pattern along the excised limbal part of the pterygium. The retrieved area was left as such with a subconjunctival injection of antibiotic and steroid. The other excised part of the pterygium was left as such. The patients were discharged on the third postoperative day with local antibiotic and steroid drops for two weeks. Follow up was done in each case after a week, fortnight, month, three months, six months and one year.

Results: There was recurrence in one case in the first group as stem cells are probably absent in the bulbar conjunctiva. In the second group there was no recurrence after one year, because new stem cells were replenished by surgery.

Conclusion: In this series,no recurrence was observed in the second group of 28 cases treated with autologous limbal conjunctival transplantation; where as recurrence occurred in 1of 2 cases treated with simple upper bulbar conjunctival transplantation. Larger group of appropriately designed studies with clearly documented follow up and statistical analysis are required before drawing conclusions about comparative effectiveness or a stem cell mechanism.

Keywords: Autologous conjunctival transplantation, Autologous limbal conjunctival transplantation, limbal stem cell, Pterygium

Received: 12-05-2026; **Accepted:** 15-06-2026; **Available Online:** 25-06-2026

This is an Open Access (OA) journal, and articles are distributed under the terms of the Creative Commons Attribution 4.0 International license, which allows others to distribute, remix, adapt, and build upon the work, even commercially, as long as appropriate credit is given and the new creations are licensed under the identical terms.

For reprints contact: drmanishkhanna@gmail.com

1. Introduction

The term stem cell was proposed for scientific use by a Russian scientist Alexander Maksimov in 1908 in the congress of Haematological society in Berlin. He postulated the existence of haemopoitic stem cells which was later discovered in human cord blood in 1978. These are present in all self renewing tissue system like skin, mucous membrane, bone marrow and regenerative system etc. These are a small group of cells and have been estimated to be from 0.5% to less than 10% of the total body cell popultion. In the eye these are presumed to be present in the corneal limbus as palisade of Vogt, ciliary body and retina.[1,2]

Pterygium is a raised fleshy wing shaped triangular growth that starts from the corner of eye invading the avascular cornea in the interpalpebral fissure exposed to the environment. It is a subconjunctival elastotic degeneration which proliferates as a vascularized granular tissue to invade the cornea by destroying the superficial layers of the stroma and Bowman's membrane, the whole being covered by conjunctival epithelium. The global incidence is 0.3–29%. In India it is 9.5–13%.The exact aetiology is not clear. However habitual exposure to dusty, windy, sunny environment with ultraviolet radiation and heredofamilial factors are the possible causes.[3]

Recent advances in the molecular tapestry of pterygium indicate that ultra violet radiation produces genetic signals leading to disturbances of Matrix metalloproteinases which

*Corresponding author: Gunasagar Das
Email: dr.gsdas@gmail.com

© 2026 Stem Cells and Cellular Therapy International

contribute to extracellular matrix remodelling. These molecular alterations lead to the damage of the limbal stem cells present in the palisade of Vogt leading to over expressation of vascular endothelial growth factor(VEGF) and angiogenesis resulting in pterygium.[4]

Its surgical removal by various procedure is the mainstay of treatment; but there is high recurrence after simple excision. So an innovative approach of stem cell therapy by autologous limbal conjunctival transplantation has been tried and evaluated in this study.

2. Materials and Methods

This is a prospective interventional observational case series study done in institutional and clinical practice approved by Institutional Ethics Committee of Konaseema Institute of Medical Science and Research Foundation, Amalapuram, Andhra Pradesh. 30 cases of primary pterygium of various age and sex undergoing surgery by the author from 2006–23 have been included in this study.

Detail ophthalmological examination was done in each case. After bare sclera excision two types of autologous conjunctivoplasty was done. In 2 cases, bulbar conjunctiva was retrieved from the upper temporal part of the globe covered by lid and transplanted into the bare area. In the rest 28 cases, upper limbal conjunctiva extending from 1 to 2 clock hour in length and 3 mm. wide (2 mm. behind and 1 mm. in front of the limbal line) was retrieved. This was transplanted circumferentially in barrage pattern in the limbal area of the excised part and fixed with four 10-0 nylon sutures at the four-corner leaving the bare sclera uncovered. The upper part of the limbal conjunctiva was left as such with a subconjunctival injection of antibiotic and steroid after surgery. **(Figure 1)**



Figure 1: Pterygium in Left eye

The patients were discharged on the third post-operative day with dark glasses, local antibiotic and steroid drops. They were evaluated at frequent intervals after a week, fortnight, one month, three months, six months and one year. Some were evaluated even after one year.

3. Results

30 cases of pterygium, undergone surgery by the author from 2006–23 have been included in this study. One case was a female, a manual labourer by occupation. Rest were male. Majority were in the age group from 15–35 years except one case of 65 years. This patient was having cystoid degeneration of the pterygium since last 30 years.

Two cases had undergone autologous conjunctivoplasty in the bare sclera part retrieved from the upper temporal quadrant of the globe. The rest 28 cases had undergone autologous limbal conjunctivoplasty in circumferential barrage pattern in the limbal area leaving the bare sclera uncovered.

In the first group there was recurrence in one case out of 02 after six months. Very often this patient was occupationally exposed to sunny, dry and dusty atmosphere after surgery.

In the second group there was smooth post-operative period without any spectacular event. There was no recurrence in any of the case after one year. The bare sclera was covered by the surrounding conjunctiva within a period of six months. However, in the elderly case of pterygium with cystoid degeneration a conjunctival growth occurred in the lower part without spreading to the cornea even after three years. The refractive error was corrected by spectacles.

4. Discussion (Figure 2), (Figure 3), (Figure 4), (Figure 5)

Pterygium can be congenital and acquired. The acquired variety appears to occur in persons frequently exposed to dry, dusty, windy and sunny atmosphere for a prolonged period probably due to ultraviolet radiation. Surgical excision is the main stay of treatment. However very often there is recurrence. It is presumed that corneal stem cells are present in the limbus in the palisade of Vogt. The main function of these stem cells is to replenish and repair the old and damaged corneal epithelium. Besides this, it prevents conjunctivalisation by not allowing neovascularization from the limbal vessels in normal cases.

In this study two types of autologous conjunctival transplantation were done. In the first type bulbar conjunctiva was retrieved from the upper temporal quadrant of the globe and transplanted to the bare sclera area following simple excision of pterygium in two cases. There was recurrence in one (50%). It may be either due to further habitual exposure to dry, dusty and sunny climate or as there are no stem cells in the upper bulbar conjunctiva; so, it could not check recurrence.

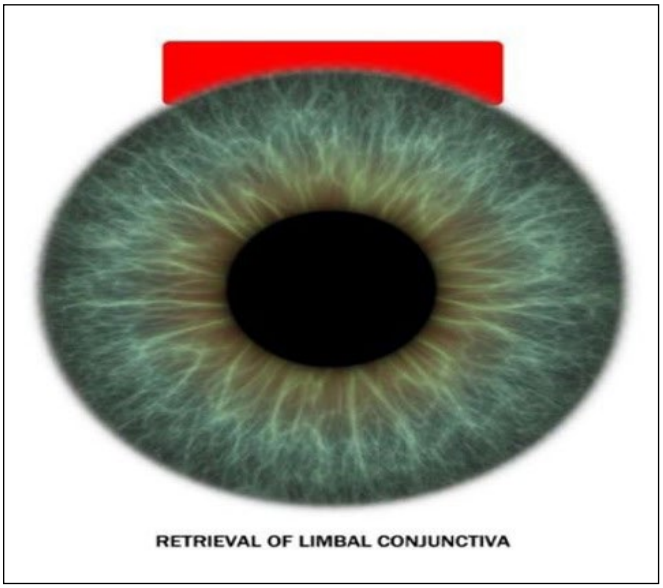

Figure 2: Schematic diagram of retrieval of limbal conjunctiva

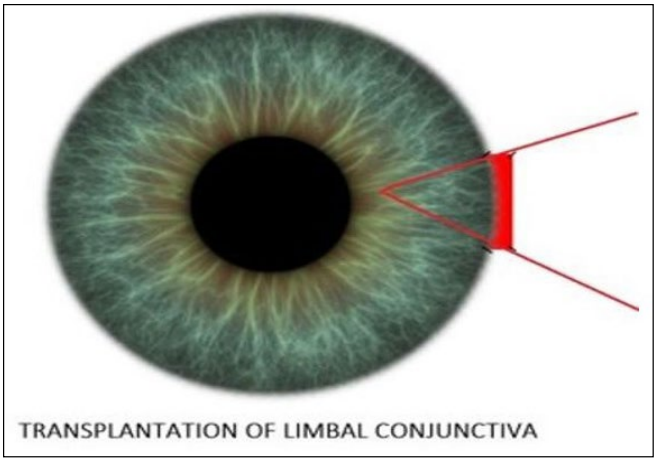

Figure 3: Schematic diagram of transplantation of Limbal conjunctiva



Figure 4: Stem cell therapy in pterygium



Figure 5: Stem cell therapy in an elderly person

In the second type after bare sclera excision, autologous limbal conjunctival transplantation in circumferential barrage pattern was done in 28 cases. In this type there was no recurrence at all even after a period of one year. Probably it is due to replenishment of partially deficient stem cells in the limbal zone.

Probably prolonged exposure to dry dusty windy and sunny climatic condition with ultraviolet radiation causes degeneration of the limbal stem cells in the interpalpebral fissure. This causes pinguecula formation and subconjunctival degeneration leading to pterygium.

Replenishment of this partial stem cell deficiency either by amniotic membrane transplantation or auto limbal conjunctival transplantation in circumferential barrage pattern prevents recurrence with less or no complication.

Tsai RJ et al., have studied reconstruction of damaged cornea by transplantation of autologous limbal epithelial cells expanded in vitro on amniotic membrane in patients with partial or total stem cell deficiency due to chemical burn (3 cases), pseudo pterygium after excision of a cyst, congenital pterygium and recurrent chronic inflammation with phlyctenular degeneration (01 case each) with a promising result.[5]

Mohamed A.E. Soliman Mehdy et al (2009) studied a group of 42 eyes of 42 patients with grade I-III primary pterygium who had undergone pterygium excision followed by superotemporal limbal and conjunctival auto graft transplantation in all cases. Within a mean follow up period of 18.26 months (10-28 months), recurrence occurred in 2 eyes (4.75%). No other significant complications were noted.[6]

Malik K.P.S. et al., studied the efficacy of suture less and glue free limbal conjunctival autograft for primary pterygium surgery and found recurrence in 1 eye (2.5%), graft dehiscence in 2 eyes (5%), and graft retraction in 3 eyes (7.5).[7]

Clearfield et al., in their study on Conjunctival autograft for pterygium have found that conjunctival autograft is associated with a lower risk of recurrence at six months after surgery than amniotic membrane transplantation.[8]

Fuest et al., in their study on New Treatment options for Pterygium opines that conjunctival autografting represents the current gold standard treatment for pterygium. Limbal conjunctival autograft is more effective than conjunctival autograft in recurrent pterygium.[9]

Mukherjee et al., in their study on Recent advances in management of Pterygium opine that the newer surgical techniques are amniotic membrane grafting, ologen transplantation and pterygium extended removal followed by extended conjunctival transplantation (P.E.R.F.E.C.T.).[10]

Paganelli et al., in their study of Conjunctival and Limbal autograft versus Amniotic membrane graft in primary pterygium surgery, have observed a recurrence of 7.61% in conjunctival autograft, 5.5% in limbal conjunctival auto graft and 9.0% in amniotic membrane graft. It was 8.99%, 6.03% and 23% in the above groups receiving sutures. Surgical techniques combining conjunctival autograft or limbal conjunctival autograft with amniotic membrane graft yielded even lower recurrence rate (1.83%).[11]

Recent studies have continued to explore the potential benefits of limbal stem cell transplantation.

Li Y et al., evaluated modified limbal stem cell transplantation combined with bandage contact lens in patients undergoing pterygium surgery. Their study assessed postoperative epithelial healing, tear-film stability, inflammatory responses, visual quality, and recurrence. The findings suggested that modified limbal transplantation, together with appropriate postoperative ocular surface protection, may improve recovery following surgery.[12]

He et al., investigated pterygium excision combined with autologous limbal stem cell transplantation, with particular attention to microvascular density, tear-film stability, and corneal wound healing. Their study provided further clinical evidence supporting the potential role of limbal tissue transplantation in ocular surface recovery after pterygium excision.[13]

A more recent review by Sahin Vural G et al., highlighted the role of limbal niche dysfunction in the pathogenesis of pterygium. The authors discussed how UV-induced injury, inflammation, and alterations in the limbal microenvironment may contribute to abnormal conjunctival growth. These

observations provide further biological support for surgical approaches aimed at restoring the limbal barrier and maintaining ocular surface stability.[14]

The findings of the present study are consistent with the general trend reported in the literature. The absence of recurrence following circumferential limbal conjunctival autografting in 28 patients over one year is encouraging and suggests that this technique may be useful in preventing postoperative recurrence. However, the marked difference in the number of patients between the two groups (2 versus 28), the limited sample size, and the absence of randomization restrict direct comparison of the two procedures. In addition, limbal stem cell function was not directly assessed, and therefore restoration of stem cell activity remains a possible explanation rather than a demonstrated mechanism.

5. Conclusion

Thirty cases of progressive pterygium had undergone autologous conjunctivoplasty after bare sclera excision. Out of which in two cases bulbar conjunctiva from the upper temporal quadrant of the globe was transplanted in the bare sclera area with one recurrence. In the rest 28 cases auto limbal conjunctival transplantation in circumferential barrage pattern was done leaving other bare part uncovered. It resulted with no recurrence after a follow up period of one year. Probably it is due to the replenishment of stem cells in the partially deficient limbal area.

6. Study Limitation

There is limitation in this study due to small sample size, unequal groups, lack of randomization, single surgeon bias and long duration.

7. Source of Funding

None.

8. Conflict of Interest

None.

9. Acknowledgement

None.

References

1. Dua HS, Saini JS, Azuara-Blanco A, Gupta P. Limbal stem cell deficiency: concept, aetiology, clinical presentation, diagnosis and management. *Indian J Ophthalmol*. 2000;48(2):83–92
2. Sangwan VS. Limbal stem cells in health and disease. *Biosci Rep*. 2001;21(4):385–405. https://doi.org/10.1023/a:1017935624867
3. Gurnani B, Tripathy K. Pterygium. 2026 Sep 14. In: StatPearls [Internet]. Treasure Island (FL): StatPearls Publishing; 2026 Jan–. Available from: https://pubmed.ncbi.nlm.nih.gov/32644333/
4. Gupta M, Arya S, Agrawal P, Gupta H, Sikka R. Unravelling the molecular tapestry of pterygium: insights into genes for diagnostic and therapeutic innovations. *Eye (Lond)*. 2024;38(15):2880–7. https://doi.org/10.1038/s41433-024-03186-y
5. Tsai RJ, Li L, Chen J. Reconstruction of damaged corneas by transplantation of autologous limbal epithelial cells(1). *Am J Ophthalmol*. 2000;130(4):543. https://doi.org/10.1016/s0002-9394(00)00746-7
6. Soliman Mahdy MAE, Bhatia J. Treatment of primary pterygium: role of limbal stem cells and conjunctival autograft transplantation. *Eur J Ophthalmol*. 2009;19(5):729-32. https://doi.org/10.1177/112067210901900507
7. Malik KP, Goel R, Gutpa A, Gupta SK, Kamal S, Mallik VK, et al. Efficacy of sutureless and glue free limbal conjunctival autograft for primary pterygium surgery. *Nepal J Ophthalmol*. 2012;4(2):230–5. https://doi.org/10.3126/nepjoph.v4i2.6537
8. Clearfield E, Muthappan V, Wang X, Kuo IC. Conjunctival autograft for pterygium. *Cochrane Database Syst Rev*. 2016;2(2):CD011349. https://doi.org/10.1002/14651858.CD011349.pub2
9. Fuest M, Mehta JS, Coroneo MT. New treatment options for pterygium. *Expert Rev Ophthalmol*. 2017;12(3):193–6. https://doi.org/10.1080/17469899.2017.1324297
10. Mukherji P, Kumar V, Kumari S. Recent advances in management of pterygium. *Int J Dent Med Sci Res*. 2022;4(1):505–10. https://doi.org/10.35629/5252-0401505510
11. Paganelli B, Sahyoun M, Gabison E. Conjunctival and limbal conjunctival autograft vs. amniotic membrane graft in primary pterygium surgery: a 30-year comprehensive review. ophthalmol ther. 2023;12(3):1501–17. https://doi.org/10.1007/s40123-023-00689-x
12. Li Y, Meng L, Gong L, Wang X, Yang X, Li T. Evaluation of the clinical efficacy of modified LSC transplantation plus BCL implantation in the treatment of pterygium. *BMC Ophthalmol*. 2024;24(1):521. https://doi.org/10.1186/s12886-024-03785-z
13. He M, Li N, Li J, Huang X. Impact of pterygium excision combined with autologous limbal stem cell transplantation on microvascular density, tear film stability, and corneal wound healing. Ann Ital Chir. 2025;96(1):47–54. https://doi.org/10.62713/aic.3800
14. Sahin Vural G, Gurdal M, Barut Selver O. Limbal Niche dysfunction in pterygium: An integrated review of pathophysiology and clinical advances. *Eur J Ophthalmol*. 2026:11206721261476757. https://doi.org/10.1177/11206721261476757

Cite this article: Das G, Dash PM. Stem cell therapy in pterygium, our experience. *Stem Cells Cell Ther Int.* 2026;1(2):84–87.